



High-flow priapism; a combined interventional approach and watchful waiting for pseudoaneurysm and cavernosal arterial-lacunar fistula

Davood Arab, Hamed Azadbar, Elaha Shahab*, Arash Ardestani Zadeh

Abstract

Priapism is an uncommon disease and defined as full or partial erection that persists beyond 4 hours and is not related to sexual stimulation. We are presenting a 33-year-old man with high-flow priapism after penile trauma when falling accidentally on an iron pipe. The patient had both arterio-lacunar fistula (ALF) and pseudoaneurysm in ultrasonography and pudendal angiography that successfully treated by super-selective embolization for pseudoaneurysm and watchful waiting for arterio-lacunar.

Keywords: Pseudoaneurysm, Priapism, Cavernosal artery

Citation: Arab D, Azadbar H, Shahab E, Ardestani Zadeh A. High-flow priapism; a combined interventional approach and watchful waiting for pseudoaneurysm and cavernosal arterial-lacunar fistula. J Renal Endocrinol. 2018;4:e15.

Copyright © 2018 The Author(s); Published by Nickan Research Institute. This is an open-access article distributed under the terms of the Creative Commons Attribution License (<http://creativecommons.org/licenses/by/4.0>), which permits unrestricted use, distribution, and reproduction in any medium, provided the original work is properly cited.

Introduction

Priapism is an uncommon disease and defined as full or partial erection that persists beyond four hours and is not related to sexual stimulation (1,2). There are two subtypes of priapism of which the rare one is high flow or non-ischemic priapism(1,2). High flow priapism is a prolonged non-rigid and non-painful erection due to unregulated excess cavernosal arterial influx (1).

Creation of an arteriolar-sinusoidal fistula secondary to traumatic laceration of cavernosal artery or its branches is the common mechanism (2).

The characteristic arteriographic finding is an arterio-lacunar fistula (ALF) but occasionally pseudoaneurysms have been reported too. Super selective arterial embolization is a therapeutic option for patients who not willing watchful waiting (2-4).

We report a case of high flow priapism secondary to traumatic pseudoaneurysm and ALF which pseudoaneurysm was treated successfully by interventional angiography and ALF was resolved by watchful waiting.

Case Presentation

A 33-year-old man referred to our clinic suffering from persistent partial erection after penile trauma when falling accidentally on an iron pipe. He had ignored the situation for 3 weeks because he had no pain or voiding symptoms or gross hematuria.

Though he mentioned normal erections with sex stimulations and initial hematuria of penis began to

subside, he felt discomfort because of persistent soft erection.

He would not remember to have erections on the first few days after injury.

On physical examination, he had partial bendable erection and there was no tenderness or ecchymosis on perineum and genitalia.

Penile blood gas analysis revealed oxygenated corporal blood (pH = 7.37, Po₂ = 168 mm Hg, Pco₂ = 48.2 mm Hg, Hco₃⁻ = 27.5 mmol/L, O₂ % = 96.6%)

Color Doppler ultrasonography of the left cavernous artery showed arteriosinusoidal fistula. Gray scale ultrasound revealed an irregular hypoechoic region due to distended lacunar space in the left corpus cavernosum (Figure 1).

Color-flow sonogram showed as a characters tic color blush extending into the cavernosal tissue and as turbulent high velocity flows on color duplex sonography. Moreover, increased cavernosal artery flow without sexual stimulation was seen and the draining veins were prominent and exhibited arterialized waveform (Figure 2). We explained and counseled the patient for available treatment options such as watchful waiting, embolization, surgical management and their advantages and complications. Our patient selected embolization because of his social and job because he could not wait for conservative management. We performed super selective pudendal angiography and embolization to relieve priapism and patient's discomfort. Pre-embolization arteriography revealed early cone-shaped blush at the

Implication for health policy/practice/research/medical education
 Priapism is an uncommon disease which has two subtypes; low and high flow priapism. In this report we present a case with high flow priapism that was treated successfully by interventional angiography.

left side corresponding to the site of fistula and small pseudoaneurysm at the right side (Figure 3). We embolized only pseudoaneurysm with glue and preferred to treat ALF in another session of angiography because of decreasing erectile dysfunction risk. After flushing the microcatheter with dextrose 5%, a mixture of N-butyl cyanoacrylate(glue) and lipiodol with a ratio of 1:5 (glue-to lipiodol ratio) was injected to occlude the

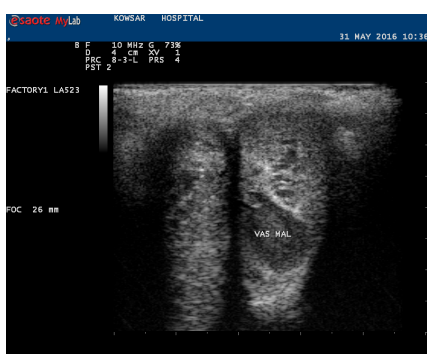


Figure 1. Gray scale ultrasound shows an irregular hypoechoic region secondary to distended lacunar spaces.

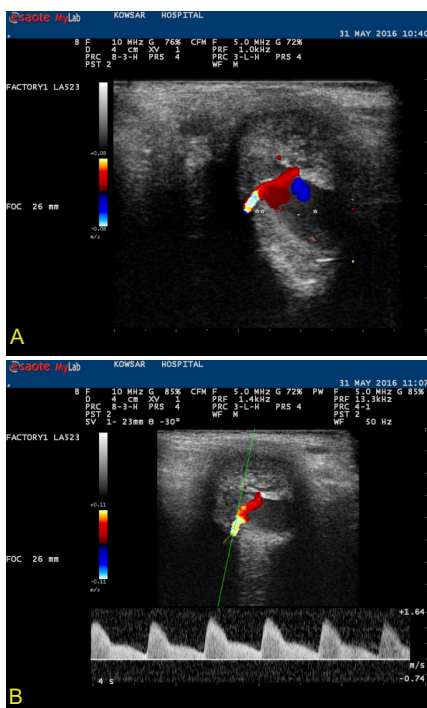


Figure 2. (A) color-flow sonogram shows an area of color flow aliasing within the left corpus cavernosum near the base of penis. This is consistent with the presence of an arterio-lacunar fistula. (B) Corresponding color flow, Doppler reveals continuous diastolic flow confirming the arterio-lacunar fistula.

pseudoaneurysm.

Complete occlusion of left cavernosal artery branch by super-selective embolization led to disappearing of pseudoaneurysm. The patient had immediate detumescence after angiography and suffered from inadequate erectile function after the procedure. He referred to our clinic 4 weeks after embolization. We repeated Doppler sonography that revealed small ALF in the left side still persisted (Figure 4).

We explained to the patient that it is better to wait for several weeks because resolving this fistula is possible without intervention.

On follow up visit after six weeks, the patient was satisfied with normal erectile function.

Discussion

High flow priapism is caused by unregulated arterial inflow to the corpora cavernosa due to an ALF or pseudoaneurysm following trauma (3-5). The treatment of high-flow priapism is not an emergency because the penis is not ischemic (2).

Effective therapy includes occluding the disrupted arterial branch while preserving erectile function by saving adjacent normal arteries (1,6).

Although the treatments of high flow priapism still remain controversial (4), definitive management should be considered and discussed with the patient in such a way that he understands the advantages, the risks and complications of treatment (7,8).

There are several treatments for high flow priapism

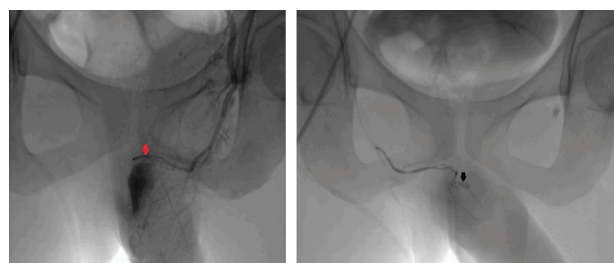


Figure 3. Arteriography shows cone shaped blush (red arrow) at left side corresponding to the site of fistula and small pseudoaneurysm at the right side (black arrow).

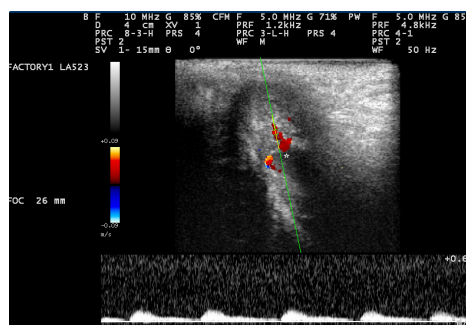


Figure 4. Four weeks after angiography, at Doppler sonography, peak systolic velocity is decreased but continuous diastolic flow is also detected.

including watchful waiting, conservative management, embolization and surgical ligation (9,10).

As ALF may be spontaneously resolved without intervention, conservative management and watchful waiting is recommended as initial management for most high flow priapism (5,9,10), especially in children (9,10). Nevertheless, it has not been clarified in the literature and there are no case reports showing observation is sufficient in the treatment of high flow priapism containing pseudoaneurysm.

Several studies mention that delayed treatment of high flow priapism results in a greater risk of erectile dysfunction due to secondary development of venous insufficiency and penile fibrosis (6,7,11,12).

Embolization of the internal pudendal artery is the second and most common management described in the literature, and surgical ligation will be the last option if the patient is not responding to embolization (7,9,10).

Cavernosal angiography and embolization have been reported with various materials including absorbable (autologous clot or gel foam or glue) or non-absorbable permanent materials like microcoil (1,13-15).

Absorbable materials have been commonly used because of inducing temporary occlusion (13-15), and gel foam injection is the preferred interventional technique (16).

Due to lowers the risk of erectile dysfunction with a greater rate of recurrence, microcoils increase the theoretical risk of impotence in future (13-15,17).

Complications of the angiography technique and abscess formation in the corpus cavernosum due to infected emboli and erectile dysfunction are disadvantages of pudendal angiography (18).

Although the patient had erectile dysfunction after angiography, it was due to remnant ALF that was treated with watchful waiting strategy in our case several weeks after angiography.

Spontaneous resolution of priapism occurred just after super selective embolization of cavernosal artery pseudoaneurysm.

Conclusion

Super selective angiography and embolization may be a safe and effective method in high flow priapism containing pseudoaneurysm.

Authors' contribution

DA, ES and AAZ managed the patient and wrote the first draft. ES wrote the final draft and supervised the patient. HA contributed to medical imaging.

Conflicts of interest

None to be declared.

Ethical considerations

Ethical issues (including plagiarism, data fabrication, double publication) have been completely observed by the authors. The patient signed the informed consent regarding this case report.

Financial disclosures

None.

References

- Montague DK, Jarow J, Broderick GA, Dmochowski RR, Heaton JP, Lue TF, et al. American Urological Association guideline on the management of priapism. *J Urol.* 2003;170:1318-24. doi: 10.1097/01.ju.0000087608.07371.ca.
- Wein AJ, Kavoussi, Louis R, Campbell, Meredith F. Campbell-Walsh Urology. 10th ed. Philadelphia, PA: Elsevier/Saunders; 2012.
- Huang YC, Harraz AM, Shindel AW, Lue TF. Evaluation and management of priapism: 2009 update. *Nat Rev Urol.* 2009;6:262-71. doi: 10.1038/nrurol.2009.50.
- Park JK, Jeong YB, Han YM. Recanalization of embolized cavernosal artery: restoring potency in the patient with high flow priapism. *J Urol.* 2001;165:2002-3.
- Lee YC, Shen JT, Shih MC, Chen CC, Chou YH, Huang CH. Bilateral superselective arterial microcoil embolization in post-traumatic high-flow priapism: a case report. *Kaohsiung J Med Sci.* 2003;19:79-83. doi: 10.1016/S1607-551X(09)70453-X.
- Alexander Tønseth K, Egge T, Kolbenstvedt A, Hedlund H. Evaluation of patients after treatment of arterial priapism with selective micro-embolization. *Scand J Urol Nephrol.* 2006;40:49-52. doi: 10.1080/00365590500338040.
- Broderick GA, Kadioglu A, Bivalacqua TJ, Ghanem H, Nehra A, Shamloul R. Priapism: pathogenesis, epidemiology, and management. *J Sex Med.* 2010;7:476-500. doi: 10.1111/j.1743-6109.2009.01625.x.
- Burnett AL, Bivalacqua TJ. Priapism: new concepts in medical and surgical management. *Urol Clin North Am.* 2011;38:185-94. doi: 10.1016/j.ucl.2011.02.005.
- Salonia A, Eardley I, Giuliano F, Hatzichristou D, Moncada I, Vardi Y, et al. European Association of Urology guidelines on priapism. *Eur Urol.* 2014;65:480-9. doi: 10.1016/j.eururo.2013.11.008.
- Hatzichristou D, Salpigidis G, Hatzimouratidis K, Apostolidis A, Tzortzis V, Bekos A, et al. Management strategy for arterial priapism: therapeutic dilemmas. *J Urol.* 2002;168:2074-7. doi: 10.1097/01.ju.0000032743.39599.ae.
- Ciampalini S, Savoca G, Buttazzi L, Gattuccio I, Mucelli FP, Bertolotto M, et al. High-flow priapism: treatment and long-term follow-up. *Urology.* 2002;59:110-3. doi: 10.1016/S0090-4295(01)01464-9.
- Hakim LS, Kulaksizoglu H, Mulligan R, Greenfield A, Goldstein I. Evolving concepts in the diagnosis and treatment of arterial high flow priapism. *J Urol.* 1996;155:541-8. doi: 10.1016/S0022-5347(01)66444-9.
- Bennett JD. Evidence-based radiology problems. High-flow post-traumatic priapism: transcatheter embolotherapy: October 2003-September 2004. *Can Assoc Radiol J.* 2003;54:207-10.
- O'Sullivan P, Browne R, McEniff N, Lee MJ. Treatment of "high-flow" priapism with superselective transcatheter embolization: a useful alternative to surgery. *Cardiovasc Intervent Radiol.* 2006;29:198-201. doi: 10.1007/s00270-005-0089-x.
- Mourikis D, Chatziioannou AN, Konstantinidis P, Panourgias E, Antoniou A, Vlachos L. Superselective microcoil embolization of a traumatic pseudoaneurysm of the cavernosal artery. *Urol Int.* 2000;64:220-2. doi: 10.1159/000030535.
- White C, Gulati M, Gomes A, Rajfer J, Raman S. Pre-embolization evaluation of high-flow priapism: magnetic resonance angiography of the penis. *Abdom Imaging.* 2013;38:588-97. doi: 10.1007/s00261-012-9936-9.
- Liu BX, Xin ZC, Zou YH, Tian L, Wu YG, Wu XJ, et al. High-flow priapism: superselective cavernous artery embolization with microcoils. *Urology.* 2008;72:571-3. doi: 10.1016/j.urology.2008.01.087.
- Sandock DS, Seftel AD, Herbener TE, Goldstein I, Greenfield AJ. Perineal abscess after embolization for high-flow priapism. *Urology.* 1996;48:308-11. doi:10.1016/S0090-4295(96)00176-8.