



An unusual cause of bilateral adrenal incidentalomas with primary adrenal lymphoma; a case report

Soraya Doustmohamadian^{1*}, Mahshid Babaiee²

Abstract

Although lymphoma can sometimes involve the extra-nodal tissues such as adrenal glands, bilateral adrenal incidentaloma with primary adrenal lymphoma is very rare. We present a 34-year-old man with abdominal discomfort, huge bilateral adrenal masses in CT scan and adrenal insufficiency by cosyntropin test. Routine investigation revealed normal K, Na and elevated serum lactate dehydrogenase (LDH). Large B-cell lymphoma was confirmed by adrenal CT guided biopsy and histopathology. Then the patient was treated with R-CHOP regimen chemotherapy protocol lonely, needless from surgery which resulted in significant reduction in adrenal masses.

Keywords: Primary adrenal lymphoma, Adrenal insufficiency, Adrenal mass

Citation: Doustmohamadian S, Babaiee M. An unusual cause of bilateral adrenal incidentalomas with primary adrenal lymphoma; a case report. J Renal Endocrinol. 2018;4:e16.

Copyright © 2018 The Author(s); Published by Nickan Research Institute. This is an open-access article distributed under the terms of the Creative Commons Attribution License (<http://creativecommons.org/licenses/by/4.0>), which permits unrestricted use, distribution, and reproduction in any medium, provided the original work is properly cited.

Introduction

In 25% of patients with lymphoma, other organs including adrenal glands may be involved in secondary (1). However primary extranodal lymphoma with endocrine involvement occurs only in 3% of patients and rarely involves the adrenal glands (2). The bilateral primary involvement of the adrenal glands by lymphoma is very rare. Bilateral primary adrenal lymphoma may be present with adrenal insufficiency, especially in bilateral adrenal involvement by huge masses (3). However, rare cases of primary adrenal lymphoma may be present with bilateral adrenal incidentalomas. According to the causes of bilateral adrenal masses, different treatments including surgery or medical therapy are existent. Thus a definitive diagnosis by pathology is necessary to choose which one of modalities is necessary for patients.

Case Presentation

A-34-year old man presented with transient epigastric fullness since 3-4 months before admission to the hospital. He had bilateral subcostal pain during deep breathing with 10 kg weight loss during 2-3 month ago. He denied decreased appetite, nausea, vomiting, fever, night sweating and dyspnea. Drug history and medical history of the patient was not significant. He was married and had two children. He did not have any familial history of malignancy such as pheochromocytoma or medullary thyroid cancer and also tuberculosis.

Clinical examination was unremarkable with normal blood pressure and temperature and especially no lymphadenopathy or hepatosplenomegaly, but skin pigmentation was observed. In abdominal sonography a well-demarcated heterogeneous hypoechoic mass at upper pole of right kidney (111× 63 mm) and near left kidney (116× 90 mm) in abdominal sonography with normal size and echo liver. Accordingly spiral abdominal CT scan revealed; bilateral huge lobulated well-demarcated hypodense solid masses within both suprarenal regions with mild heterogeneous enhancement. There was not any calcification or necrosis in mass. Right adrenal mass had 127 × 84 × 94 mm size, while left adrenal mass was 120 × 88 × 103 mm in diameter) (Figure 1). Routine investigations revealed normocytic normochromic anemia and elevated erythrocyte sedimentation rate (ESR; 85 mm 1hr). WBC count was 11000/μL with 55% lymphocyte. Serum lactate dehydrogenase (LDH) was 795 U/L (normal 85-450 U/L). Serum electrolytes were normal. The basal serum cortisol level was 8 μ/dL (normal range 5-20 μ/dL), and stimulated cortisol was less than 10 μ/dL (reference normal value >20 μ/dL). Additionally serum ACTH was 521 pg/mL (normal range 7-63 pg/mL). Besides 24 hours urine analysis for catecholamine was normal. In the presence of hyperpigmentation and bilateral adrenal masses with hypocortisolism, primary adrenal insufficiency was the most likely diagnosis. Adrenal insufficiency by cosyntropin test was confirmed. Likewise, PPD test was

Received: 1 April 2018, Accepted: 10 May 2018, ePublished: 28 May 2018

¹Department of Internal Medicine, School of Medicine, Semnan University of Medical Science, Semnan, Iran. ²Department of Internal Medicine, School of Medicine, Shahrekord University of Medical Science, Shahrekord, Iran.

*Corresponding Author: Soraya Doostmohamadian, Email: sorayadoust@yahoo.com

■ Implication for health policy/practice/research/ medical education

Primary adrenal lymphoma has very grave prognosis with low survival. The prognosis of some cases is less than 5 months. The effective factors on the prognosis of primary adrenal lymphoma include the following; older age, larger tumor size, high levels of LDH, and presence of adrenal insufficiency.

negative for tuberculosis and chest CT did not reveal any mediastinal lymphadenopathy, or parenchymal lesion or calcification.

For replacement therapy of primary adrenal insufficiency, prednisolone 5mg daily and fludrocortisone 0.1 mg daily was started. One week after administration, blood pressure and electrolyte were normal. Then, for evaluation of nonfunctional bilateral adrenal incidentaloma, the patient referred for CT guided biopsy after receiving stress dose of hydrocortisone. Adrenal mass biopsy revealed malignant lymphoma. Immunohistochemistry finding was consistent with high-grade large B cell lymphoma.

Then chemotherapy with R-CHOP regimen only, needless from surgery was started. Three months after initiation of chemotherapy a significant mass reduction by abdominal imagine was detected (Figure 2).

Discussion

An adrenal “incidentaloma” is an adrenal mass, often larger than 1 cm that suddenly and unexpectedly is discovered during radiologic images that performed for any reason other than evaluation for adrenal disease. Adrenal incidentaloma occurs usually as unilateral adrenal mass but, may be present with bilateral adrenal involvement. The usual causes of bilateral adrenal incidentaloma are bilateral adrenal metastases, congenital adrenal hyperplasia, bilateral cortical adenomas, and disseminated infections like tuberculosis, histoplasmosis and cryptococcosis. The common sources of adrenal metastasis are breast cancer, lung and gastrointestinal carcinoma and malignant melanoma. Clinically adrenal insufficiency due to adrenal metastasis occurs when adrenal involvement is bilateral and at least 90% of adrenal tissue is destroyed (4).

Lymphoma disseminating to both adrenals is one causes of bilateral masses. The possibility of adrenal involvement in non-Hodgkin's lymphoma was reported approximately 24% of cases in an autopsy study (5), and in 4% of cases assessed by computed tomography (CT) scan (6). In series studies of 127 patients with non-Hodgkin's lymphoma, adrenal insufficiency has been reported only in 4 cases of 127 patients with adrenal involvement (7,8). Our case with huge bilateral adrenal masse presented with primary adrenal insufficiency thus replacement therapy was done. Primary adrenal lymphoma is extremely rare (8). Mantazios et al reviewed clinicopathological features of 84 cases with primary adrenal lymphoma. The mean age

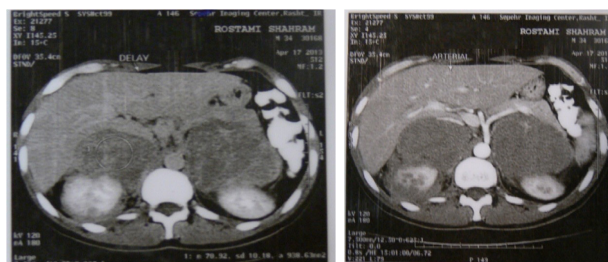


Figure 1. Abdominal CT scan showing large heterogeneous adrenal masses.

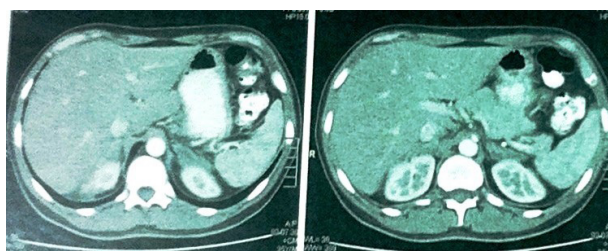


Figure 2. Abdominal CT scan showing a significant reduction in adrenal masses post-chemotherapy.

of presentation was 65 years and was more common in men (were twice as likely as the women). Primary adrenal lymphoma presented with bilateral adrenal masses with maximum diameter around 8 cm and adrenal insufficiency in 70% of cases (8).

Primary adrenal lymphoma is difficult to differentiate from adrenal carcinoma. However radiological images including ultrasound, CT scans, and magnetic resonance imaging (MRI) may be useful for differentiating between adrenal masses. In addition to CT findings, high serum LDH is also a sign of malignancy. Primary adrenal lymphoma should be considered in bilateral adrenal masses, in patients with increased serum LDH, older patients, men, presence of primary adrenal insufficiency and in the presence of large adrenal mass with diameter >6 cm (9). The definitive diagnosis of adrenal lymphoma is confirmed with pathology by ultrasound or CT-guided biopsy. More than 80% of primary adrenal lymphomas in histopathology are reported with diffuse large B-cell lymphoma (10-12).

Primary adrenal lymphoma has very grave prognosis with low survival. The prognosis of some cases is less than five months. The effective factors on the prognosis of primary adrenal lymphoma include the following; older age, larger tumor size, high levels of LDH, and presence of adrenal insufficiency (13).

Treatment of primary adrenal lymphoma is not satisfactory. Different methods were suggested for the treatment of adrenal lymphoma including surgery, chemotherapy, and radiotherapy or combination therapy. In fact, the choice method is not clear and the best modality should be selected based on low side effects and more benefits. Although complete remission of disease

after chemotherapy alone may not achieve, Based on side effects of bilateral adrenalectomy, it is not clear whether combination therapy with surgery and chemotherapy have more benefit or better survival (14).

Conclusion

Our patient with primary adrenal lymphoma treated only with R-CHOP regimen chemotherapy without surgery, and despite the poor prognosis according to what that mentioned above, this case returned to our clinic after three months with a significant reduction in tumor size in new adrenal CT. Because of lost to follow up, we do not have a precise knowledge of patient survival.

Authors' contribution

SD managed the patient and wrote the first draft. SD and MB wrote the final draft and managed the patient.

Conflicts of interest

There were no points of conflicts.

Ethical considerations

Ethical issues (including plagiarism, data fabrication, double publication) have been completely observed by the authors. The patient has given his informed consent regarding this case report.

Funding/ Support

None.

References

- Miyake O, Namiki M, Sonoda T, Kitamura H. Secondary involvement of genitourinary organs in malignant lymphoma. *Urologia internationalis*. 1987;42:360-2. doi: 10.1159/000281993.
- López-Guillermo A, Colomo L, Jiménez M, Bosch F, Villamor N, Arenillas L, et al. Diffuse large B-cell lymphoma: clinical and biological characterization and outcome according to the nodal or extranodal primary origin. *J Clin Oncol*. 2005;23:2797-804. doi: 10.1200/JCO.2005.07.155.
- Horiguchi K, Hashimoto K, Hashizume M, Masuo T, Suto M, Okajo J, et al. Primary bilateral adrenal diffuse large B-cell lymphoma demonstrating adrenal failure. *Intern Med*. 2010;49:2241-6. doi: 10.2169/internalmedicine.49.3941.
- Huminer D, Garty M, Lapidot M, Leiba S, Borohov H, Rosenfeld JB. Lymphoma presenting with adrenal insufficiency: adrenal enlargement on computed tomographic scanning as a clue to diagnosis. *Am J Med*. 1988 Jan;84(1):169-72. doi: 10.1016/0002-9343(88)90029-0.
- Rosenberg SA, Diamond HD, Jaslowitz B, Craver LF. Lymphosarcoma: a review of 1269 cases. *Medicine (Baltimore)*. 1961;40:31-84.
- Ellis R, Read D. Bilateral adrenal non-Hodgkin's lymphoma with adrenal insufficiency. *Postgrad Med J*. 2000;76:508-9. doi: 10.1136/pmj.76.898.508.
- Gamelin E, Beldent V, Rousselet MC, Rieux D, Rohmer V, Ifrah N, et al. Non-Hodgkin's lymphoma presenting with primary adrenal insufficiency a disease with an underestimated frequency? *Cancer*. 1992;69:2333-6.
- Kita M, Mandala E, Saratzis A, Ventzi L, Venizelos I, Keryttopoulos P, et al. Primary adrenal lymphoma presenting as Addison's disease. Case report and review of the literature. *Exp Clin Endocrinol Diabetes*. 2008 Jun;116:363-5.
- Aziz SA, Laway BA, Rangreze I, Lone MI, Ahmad SN. Primary adrenal lymphoma: Differential involvement with varying adrenal function. *Indian J Endocrinol Metab*. 2011;15:220-3. doi: 10.4103/2230-8210.83414.
- Wang J, Sun NC, Renslo R, Chuang C-C, Tabbarah HJ, Barajas L, et al. Clinically silent primary adrenal lymphoma: a case report and review of the literature. *Am J Hematol*. 1998;58:130-6. doi: 10.1002/(SICI)1096-8652(199806)58:2<130::AID-AJH8>3.0.CO;2-T.
- Schnitzer B, Smid D, Lloyd RV. Primary T-cell lymphoma of the adrenal glands with adrenal insufficiency. *Hum Pathol*. 1986;17:634-6.
- Shea TC, Spark R, Kane B, Lange RF. Non-Hodgkin's lymphoma limited to the adrenal gland with adrenal insufficiency. *Am J Med*. 1985;78:711-4. doi: 10.1016/0002-9343(85)90420-6.
- Salvatore JR, Ross RS. Primary bilateral adrenal lymphoma. *Leuk Lymphoma*. 1999;34:111-7. doi: 10.3109/10428199909083386.
- Coiffier B, Lepage E, Briere J, Herbrecht R, Tilly H, Bouabdallah R, et al. CHOP chemotherapy plus rituximab compared with CHOP alone in elderly patients with diffuse large-B-cell lymphoma. *N Engl J Med*. 2002;346:235-42. doi: 10.1056/NEJMoa011795.